

Effect of childhood atropine treatment on adult choroidal thickness using sequential deep learning-enabled segmentation

Yong Li^{a,b}, Damon Wong^{a,c,d}, Syna Sreng^{a,c}, Joey Chung^a, Angeline Toh^a, Han Yuan^b,
Leila Sara Eppenberger^{a,e}, Cheryl Leow^a, Daniel Ting^{a,b,f}, Nan Liu^b,
Leopold Schmetterer^{a,b,c,d,g,h,i}, Seang-Mei Saw^{a,b,j}, Jost B. Jonas^{a,i,k},
Audrey Chia^{a,b}, Marcus Ang^{a,b,*}

^a Singapore Eye Research Institute, Singapore National Eye Centre, Singapore, Singapore

^b Duke-NUS Medical School, National University of Singapore, Singapore, Singapore

^c SERI-NTU Advanced Ocular Engineering (STANCE), Singapore, Singapore

^d School of Chemistry, Chemical Engineering and Biotechnology, Nanyang Technological University, Singapore, Singapore

^e Health Sciences and Technology, ETH Zurich, Zurich, Switzerland

^f Byers Eye Institute, Sandford University, Palo Alto, CA, USA

^g Department of Clinical Pharmacology, Medical University Vienna, Vienna, Austria

^h Center for Medical Physics and Biomedical Engineering, Medical University Vienna, Vienna, Austria

ⁱ Institute of Molecular and Clinical Ophthalmology, Basel, Switzerland

^j Saw Swee Hock School of Public Health, National University of Singapore, Singapore, Singapore

^k Privatpraxis Prof Jonas and Dr Panda-Jonas, Heidelberg, Germany

ARTICLE INFO

Keywords:

Atropine
Myopia
Choroidal thickness
Optical coherence tomography
SS-OCT

ABSTRACT

Purpose: To describe choroidal thickness measurements using a sequential deep learning segmentation in adults who received childhood atropine treatment for myopia control.

Design: Prospective, observational study.

Methods: Choroidal thickness was measured by swept-source optical coherence tomography in adults who received childhood atropine, segmented using a sequential deep learning approach.

Results: Of 422 eyes, 94 (22.3 %) had no previous exposure to atropine treatment, while 328 (77.7 %) had received topical atropine during childhood. After adjusting for age, sex, and axial length, childhood atropine exposure was associated with a thicker choroid by 32.1 μm (95 % CI, 9.2–55.0; $P = 0.006$) in the inner inferior, 23.5 μm (95 % CI, 1.9–45.1; $P = 0.03$) in the outer inferior, 21.8 μm (95 % CI, 0.76–42.9; $P = 0.04$) in the inner nasal, and 21.8 μm (95 % CI, 2.6–41.0; $P = 0.03$) in the outer nasal. Multivariable analysis, adjusted for age, sex, atropine use, and axial length, showed an independent association between central subfield choroidal thickness and the incidence of tessellated fundus ($P < 0.001$; OR, 0.97; 95 % CI, 0.96–0.98).

Conclusions: This study demonstrated that short-term (2–4 years) atropine treatment during childhood was associated with an increase in choroidal thickness of 20–40 μm in adulthood (10–20 years later), after adjusting for age, sex, and axial length. We also observed an independent association between eyes with thicker central choroidal measurements and reduced incidence of tessellated fundus. Our study suggests that childhood exposure to atropine treatment may affect choroidal thickness in adulthood.

Introduction

Myopia affects more than two billion individuals worldwide, and the development of high myopia is associated with sight-threatening complications, such as myopic maculopathy, which can lead to irreversible

vision loss.^{1–5} Topical atropine eye drops have been recognized as an effective intervention to slow the onset and progression of myopia in children, potentially reducing the future development of high myopia in adulthood.^{6–14} However, long-term studies on the effects and benefits of childhood myopia interventions are limited. The Atropine Treatment

* Correspondence to: Singapore Eye Research Institute, Singapore National Eye Centre, 11 Third Hospital Avenue, Singapore 168751, Singapore.

E-mail address: marcus.ang@sneec.com.sg (M. Ang).

<https://doi.org/10.1016/j.apjo.2024.100107>

Received 23 July 2024; Received in revised form 20 September 2024; Accepted 26 September 2024

Available online 6 October 2024

2162-0989/© 2024 Published by Elsevier Inc. on behalf of Asia-Pacific Academy of Ophthalmology and Academy of Asia-Pacific Professors of Ophthalmology. This is an open access article under the CC BY-NC-ND license (<http://creativecommons.org/licenses/by-nc-nd/4.0/>).

Long-term Assessment Study (ATLAS) aimed to address this gap and demonstrated that short-term (2–4 year) childhood atropine treatment was insufficient to influence the final refractive error in adulthood, although it suggested long-term safety with no increased incidence of ocular complications.¹⁵

The choroid has long been of great interest in the field of myopia due to its important role in eye growth and emmetropization. It provides nutrients and oxygen to the sclera, retinal pigment epithelium, and outer retinal layers, and may also secrete retina-derived signals to the sclera.¹⁶ The choroid tends to thin in response to myopia-induced visual stimuli,¹⁷ and a thinner choroid has been associated with a higher risk of myopic maculopathy, myopic choroidal neovascularization, and lacquer cracks.^{17–19} Reduced choroidal thickness is also associated with a higher risk of myopic maculopathy progression, independent of axial length.²⁰ Improvements in swept-source optical coherence tomography (SS-OCT) technology now allow for detailed, repeatable, in vivo analyses of choroidal thickness in the posterior pole.^{21,22} While deep learning architectures have been utilized for segmentation in medical imaging,^{23,24} their use in choroidal layer segmentation has been limited to cross-sectional B-scans,^{25,26} which are prone to noise during the segmentation process.

The short-term effects of various myopia control interventions on the choroid have been documented. For example, choroidal thickening was observed in eyes following orthokeratology treatment,²⁷ with this short-term increase exhibiting a negative correlation with axial elongation.²⁸ An increase in choroidal thickness was also observed in children who received 1 % atropine for one week²⁹ or 0.01 % atropine for less than eight weeks.^{30,31} However, another study reported that while 1 % atropine could increase choroidal thickness, 0.01 % atropine caused a decrease in choroidal thickness after six months of treatment.³² Despite these findings, the long-term effects and downstream implications of these choroidal changes, particularly in adults who received childhood atropine treatment, have not been extensively studied. Thus, we aim to describe the choroidal thickness profiles using sequential deep learning-enabled segmentation in adults who were treated with atropine for myopia control during their childhood.

Methods

Study population

All participants from the ATLAS study were eligible for inclusion in this study.^{8,33} The demographic characteristics of the ATLAS study have been previously detailed.^{8,9,13,15,33} Written informed consent was obtained from all participants following eligibility screening. Each participant received a stipend of 50 Singapore dollars (approximately 36.47 US dollars) per completed visit to cover transportation and other expenses associated with the examination. The study was conducted in accordance with the tenets of the Declaration of Helsinki, and ethics approval was granted by the Singapore Eye Research Institute Review Board (No. 2020/2249). This study adhered to the Strengthening the Reporting of Observational Studies in Epidemiology (STROBE) reporting guidelines.

Ocular examinations

Participants underwent a comprehensive ocular examination. Autorefractometry was performed under cycloplegic conditions using a Topcon Auto Kerato-Refractometer (Topcon Corp., Tokyo, Japan), yielding three readings with a maximum range of 0.50 D. The mean values of the three readings were taken for further statistical analysis. The SE of the refractive error was calculated as the spherical refractive error plus half of the cylindrical refractive error. Ocular biometry measurements, including axial length, anterior chamber depth, and corneal curvature radius, were obtained using laser interferometry (IOL-Master, Carl Zeiss Meditec, Jena, Germany). Five readings were taken

and averaged. The axial length measurements were not allowed to vary by more than 0.05 mm. Fundus photographs of the posterior fundus were taken using the DRI OCT Triton (Topcon, Tokyo, Japan) and assessed by two examiners (Y.L. and J.C.) to determine the degree and progression of tessellated fundus after the clinical trials.

Measurement of choroidal thickness

Choroidal thickness was measured using SS-OCT (Topcon DRI OCT Triton; Topcon Corp., Tokyo, Japan) with a wavelength of 1050 nm at a scanning speed of 100,000 A-scans per second. A 12-line radial scan pattern centred on the fovea, with a scan length of 6 mm and a resolution of 1059 × 400 pixels, was employed. Each image represented an average of 32 overlapped consecutive scans. The choroidal layers were automatically segmented using the built-in software, with manual corrections made when the software misidentified the layer boundaries. All images were inspected and manually corrected by two trained researchers (Y.L. and J.C.) in a masked manner. Choroidal thickness was defined as the sagittal distance between Bruch's membrane and the choroid-sclera interface (Fig. 1A).³⁴ The Early Treatment Diabetic Retinopathy Study (ETDRS) grid was employed to calculate the average choroidal thickness within each grid sector using the embedded software.³⁵ The central foveal, parafoveal, and perifoveal circles had diameters of 1 mm, 3 mm, and 6 mm, respectively, and were further divided into superior, inferior, temporal, and nasal sectors (Fig. 1B). Using the same ETDRS grid, another custom-built sequential deep learning algorithm was employed to process the SS-OCT scans segmentation and obtain regional choroidal thickness readings within the macular region (6 mm in diameter) (Fig. 1C–D).³⁶ Additionally, a more detailed grid was applied in the inner and outer nasal quadrants (Fig. 1E). The details of the sequential deep learning approach for choroidal layer segmentation, particularly in highly myopic eyes, have been previously described.^{36,37} The sequential segmentation achieved two-dimensional segmentation by taking the three-dimensional (3D) context between slices into consideration (Fig. 1C).³⁶ The networks take a sub-volume consisting of a single B-scan slice and its neighbouring slices as input, learning the sub-volume's 3D context in a sequential manner using bidirectional convolutional long short-term memory.³⁸

Statistical analysis

All analyses were performed using the statistical software R, version 4.1.0 (The R Foundation for Statistical Computing). Mean and standard deviation (SD) were calculated for continuous variables. Mean differences or odds ratios (ORs) with corresponding 95 % confidence intervals (CIs) were calculated. When comparing effects between groups in ATOM2, measurements from both eyes were pooled in a combined analysis using Huber-White robust standard errors to allow for the correlation between the two eyes of each participant.³⁹ Analysis of covariance was used to estimate mean choroidal thickness in relation to atropine exposure. For each choroidal thickness parameter, two multivariable models were constructed. In model 1, age and sex, which are known determinants of choroidal thickness,^{40,41} were included to serve as a basic model with minimal adjustment. We conducted a univariate analysis of all potential factors with choroidal thickness. Axial length was found to be a determinant and was therefore included in model 2. In all statistical analyses, the mean and sectoral choroidal thickness were compared between atropine and placebo groups, as well as among different concentrations of atropine or durations of treatment. Multivariate multiple regression analysis was employed to assess the association between central subfield choroidal thickness and the incidence of tessellated fundus. The Bland-Altman plot was used to evaluate mean differences between choroidal thickness measurements obtained using the Triton built-in software and the custom-built deep learning approach. A two-sided *P* value of less than 0.05 was considered statistically significant.

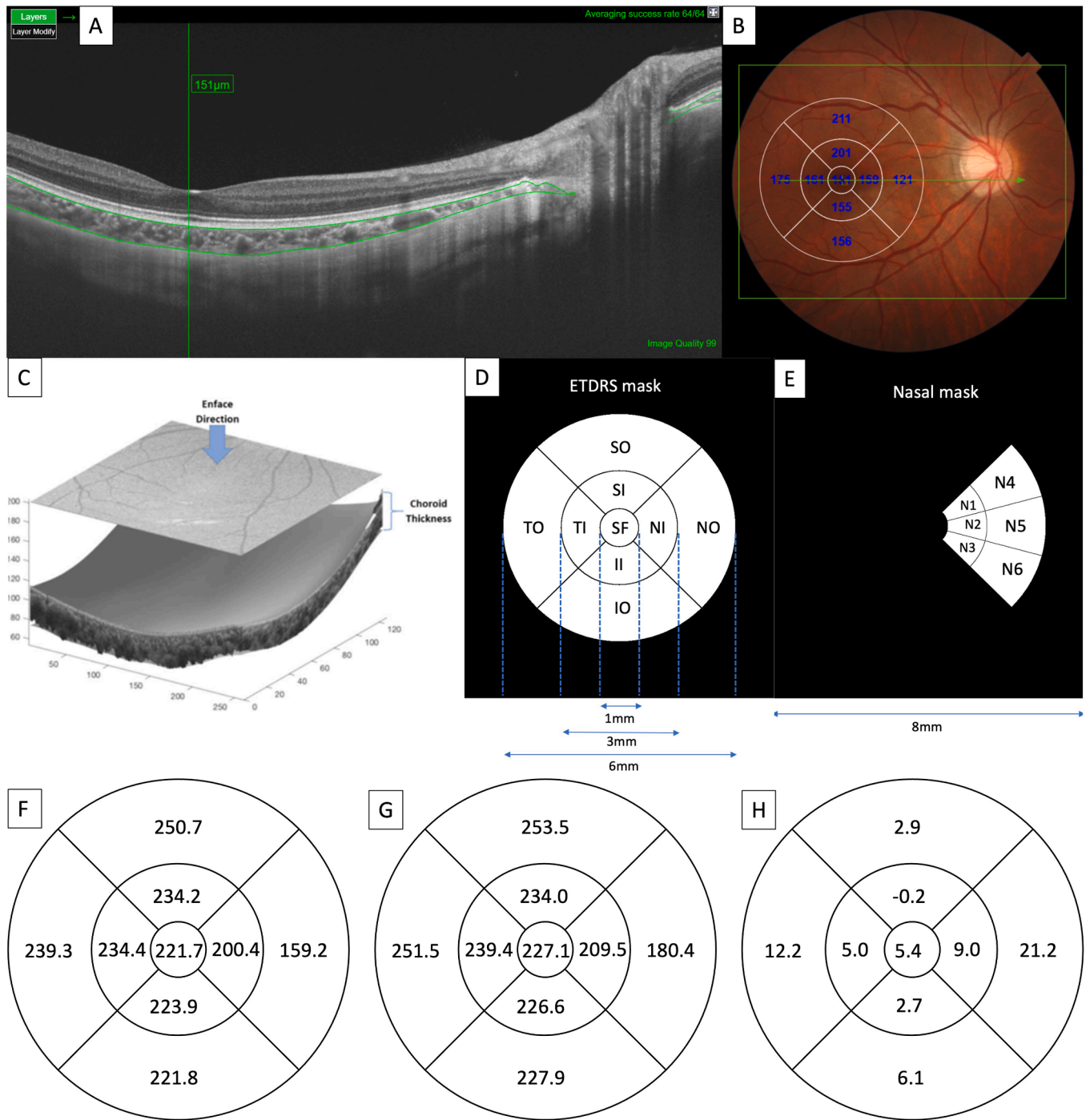


Fig. 1. The measurement of choroidal thickness using swept-source optical coherence tomography. (A) Choroidal thickness was measured as the distance between the Bruch membrane (upper green line) and the choroid-sclera interface (lower green line). (B) The Early Treatment Diabetic Retinopathy Study grid with the Triton built-in software was applied to measure the mean choroidal thickness for each sector. (C) The segmentation of the choroid with a custom-built deep learning approach was applied to measure the choroidal thickness. (D) The Early Treatment Diabetic Retinopathy Study grid was masked to generate the mean choroidal thickness for each sector. (E) A further more detailed nasal grid was masked to generate the mean choroidal thickness within the nasal sectors. (F) The mean choroidal thickness generated by the built-in software. (G) The mean choroidal thickness generated by the custom-built approach. (H) The mean differences of the choroidal thickness of the two methods.

Results

A total of 229 participants (71 from ATOM1, 158 from ATOM2) participated in the study. We analysed associations between choroidal thickness in adulthood and previous childhood atropine treatment in 422 eyes of 211 participants (63 from ATOM1, 148 from ATOM2) who had completed the initial two years of clinical trials. They were

categorized according to the initial atropine treatment concentration (no atropine, 0.01 %, 0.1 %, 0.5 %, and 1 % atropine) or therapy duration (no atropine, 2 years, and 4 years) during childhood (Supplementary Table 1). Mean choroidal thickness readings, obtained using both the built-in measurement device (Fig. 1F) and the custom-built deep learning approach (Fig. 1G), are listed in Supplementary Table 2. Bland-Altman plots comparing the two measurements are

presented in Fig. 2. The mean differences between these two measurements varied less than 10 μm in most of the sectors, except for the outer temporal (12.2 (17.6) μm) and outer nasal (21.2 (21.1) μm) sectors (Fig. 1H).

Eyes treated with childhood atropine had a greater mean choroidal thickness in the inner inferior (mean difference, 32.1 μm; 95 % CI, 9.2–55.0 μm; $P = 0.006$), outer inferior (mean difference, 23.5 μm; 95 % CI, 1.9–45.1 μm; $P = 0.03$), inner nasal (mean difference, 21.8 μm; 95 % CI, 0.76–42.9 μm; $P = 0.04$), and outer nasal sectors (mean difference, 21.8 μm; 95 % CI, 2.6–41.0 μm; $P = 0.03$) compared to eyes that had not received atropine, after adjusting for age, sex, and axial length (Table 1). Eyes treated in childhood with a low dose (0.01 %) of atropine (150 eyes) had a greater mean choroidal thickness in the outer superior (mean difference, 55.9 μm; 95 % CI, 2.4–109.5 μm; $P = 0.04$), inner inferior (mean difference, 66.7 μm; 95 % CI, 13.9–119.5 μm; $P = 0.01$), outer inferior (mean difference, 52.0 μm; 95 % CI, 1.2–102.9 μm; $P = 0.04$), and outer nasal (mean difference, 48.0 μm; 95 % CI, 2.6–93.4 μm; $P = 0.04$) compared to non-atropine-treated eyes, after adjusting for the same factors (Table 2). Additionally, 268 eyes were analyzed for the association between choroidal thickness in adulthood and four years of childhood atropine treatment. In this group, choroidal thickness was 40–60 μm greater in the outer superior and one outer nasal (N6) sector compared to eyes without atropine treatment, following adjustment for

the same factors (Table 3).

Multivariate multiple analysis, adjusted for age, sex, and axial length, showed an independent association between central subfield choroidal thickness and the incidence of tessellated fundus in all study participants ($P < 0.001$; OR, 0.97; 95 % CI, 0.96–0.98). A similar independent association between central subfield choroidal thickness and the incidence of tessellated fundus was observed in ATOM2 participants after adjusting for the same factors ($P < 0.001$; OR, 0.97; 95 % CI, 0.96–0.98). Furthermore, eyes treated with 0.5 % atropine during childhood were found to be independently associated with a higher incidence of tessellated fundus compared to eyes treated with 0.01 % atropine ($P = 0.04$; OR, 3.02; 95 % CI, 1.10–8.90).

Discussion

In this study, we examined choroidal thickness profiles in adults who were treated with short-term (2–4 years duration) topical atropine eyedrops for myopia control during their childhood. To our knowledge, our study is the first to describe the association between childhood atropine treatment and choroidal thickness in early adulthood utilizing the ATLAS cohort, which followed subjects for 10–20 years after cessation of myopia control. Recent advancements in SS-OCT technology for choroidal imaging, characterized by its longer beam wavelength,

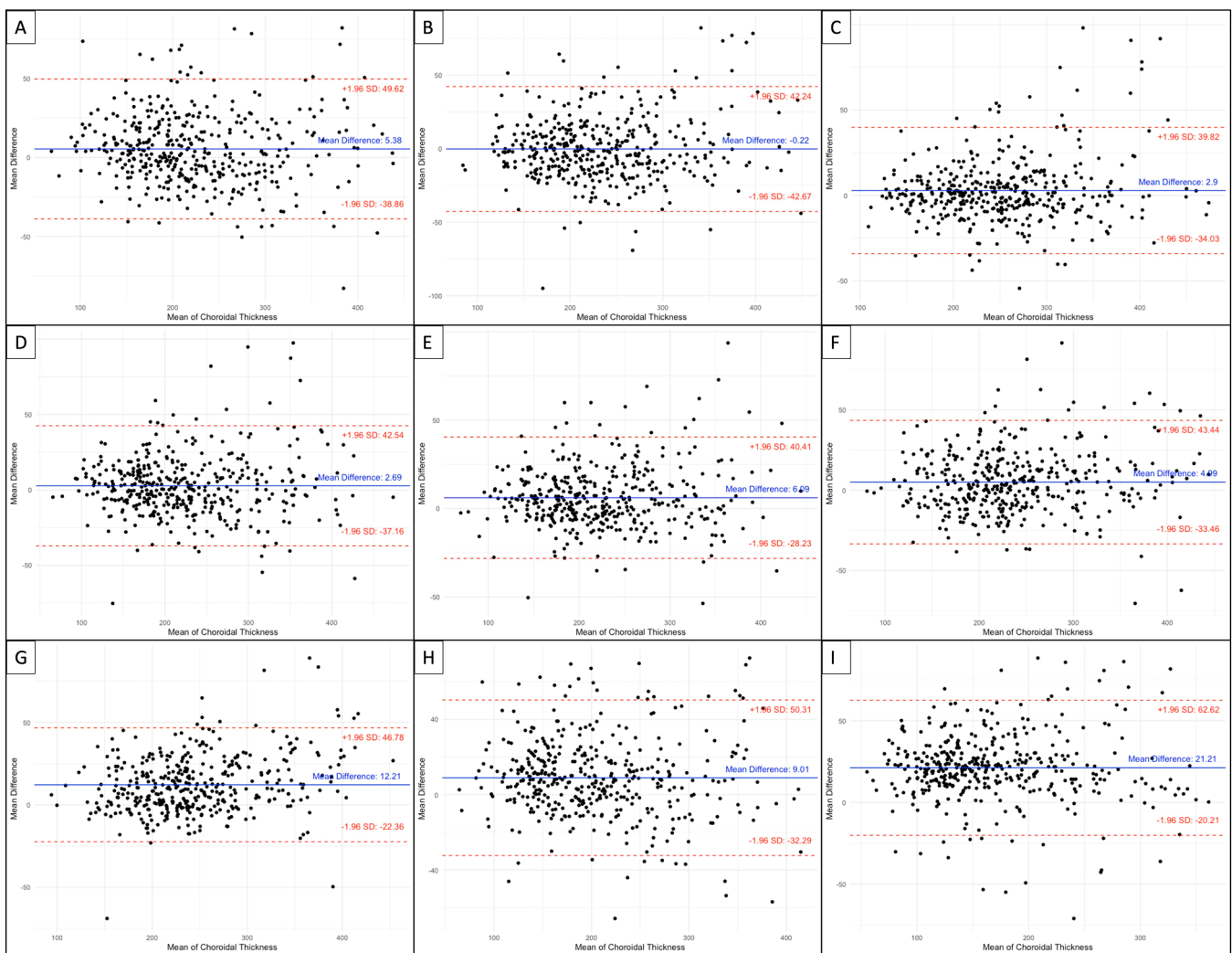


Fig. 2. BA plots of the mean choroidal thickness using the built-in and custom-built deep learning methods. (A) central subfield sector. (B) inner superior sector. (C) outer superior sector. (D) inner inferior sector. (E) outer inferior sector. (F) inner temporal sector. (G) outer temporal sector. (H) inner nasal sector. (I) outer nasal sector.

Table 1
Association of Choroidal Thickness in Adulthood with Childhood Atropine Treatment.

CT at Different Sectors*, μm	Mean (95 % CI)		Mean Difference (95 % CI)	P Value	Adjusted R ²
	No Atropine (n = 94)	With Atropine (n = 328)			
Model 1^a					
Central subfield CT	210.3 (190.0–230.7)	232.4 (223.6–241.2)	22.1 (–2.4–46.5)	0.08	0.04
Inner superior CT	226.1 (206.3–245.9)	236.7 (228.0–245.5)	10.6 (–13.4–34.6)	0.38	0.02
Outer superior CT	244.8 (224.9–264.8)	256.3 (247.5–265.1)	11.4 (–12.6–35.5)	0.35	0.02
Inner inferior CT	198.3 (177.1–219.5)	235.3 (226.1–244.4)	37.0 (11.5–62.4)	0.005	0.06
Outer inferior CT	206.0 (186.6–225.4)	235.0 (226.5–243.6)	29.0 (5.6–52.4)	0.02	0.06
Inner temporal CT	224.6 (204.1–245.1)	244.1 (235.3–253.0)	19.5 (–5.1–44.2)	0.12	0.03
Outer temporal CT	237.4 (218.1–256.7)	256.0 (247.7–264.3)	18.6 (–4.6–41.8)	0.12	0.04
Inner nasal CT	190.4 (171.0–209.8)	215.6 (207.1–224.2)	25.2 (1.8–48.6)	0.04	0.05
Outer nasal CT	161.7 (144.5–179.0)	187.0 (179.4–194.7)	25.3 (4.5–46.2)	0.02	0.06
N1 CT	197.1 (177.7–216.5)	219.4 (210.9–228.0)	22.4 (–1.0–45.7)	0.06	0.05
N2 CT	184.2 (164.8–203.6)	213.5 (205.0–222.1)	29.3 (6.0–52.7)	0.01	0.06
N3 CT	184.5 (164.4–204.5)	216.8 (208.0–225.7)	32.4 (8.3–56.5)	0.009	0.06
N4 CT	178.8 (160.3–197.3)	199.5 (191.3–207.6)	20.7 (–1.6–42.9)	0.07	0.04
N5 CT	150.5 (133.4–167.6)	177.0 (169.4–184.5)	26.5 (5.9–47.1)	0.01	0.06
N6 CT	156.9 (138.7–175.1)	188.1 (180.1–196.1)	31.2 (9.3–53.1)	0.005	0.06
Model 2^b					
Central subfield CT	212.0 (193.6–230.5)	231.8 (223.9–239.7)	19.7 (–2.4–41.8)	0.08	0.23
Inner superior CT	227.0 (208.6–245.4)	236.3 (228.2–244.3)	9.3 (–12.9–31.5)	0.41	0.18
Outer superior CT	245.9 (226.9–264.8)	255.9 (247.6–264.2)	10.0 (–12.9–32.9)	0.39	0.14
Inner inferior CT	202.1 (183.0–221.2)	234.2 (226.0–242.4)	32.1 (9.2–55.0)	0.006	0.26
Outer inferior CT	210.3 (192.4–228.2)	233.9 (226.1–241.7)	23.5 (1.9–45.1)	0.03	0.22
Inner temporal CT	226.5 (207.8–245.1)	243.4 (235.5–251.4)	17.0 (–5.4–39.4)	0.14	0.22
Outer temporal CT	238.9 (221.0–256.8)	255.4 (247.8–263.0)	16.5 (–5.0–38.0)	0.13	0.20
Inner nasal CT	193.0 (175.5–210.5)	214.8 (207.2–222.4)	21.8 (0.76–42.9)	0.024	0.25
Outer nasal CT	164.5 (148.6–180.4)	186.3 (179.3–193.3)	21.8 (2.6–41.0)	0.03	0.22
N1 CT	200.2 (182.6–217.8)	218.4 (210.7–226.1)	18.2 (–3.0–39.5)	0.09	0.23
N2 CT	187.3 (169.8–204.8)	212.6 (205.0–220.2)	25.3 (4.2–46.4)	0.02	0.26
N3 CT	188.2 (170.2–206.1)	215.7 (207.9–223.6)	27.6 (6.0–49.2)	0.01	0.26
N4 CT	180.9 (163.8–198.1)	198.8 (191.3–206.3)	17.9 (–2.7–38.5)	0.09	0.20
N5 CT	153.3 (137.6–169.1)	176.2 (169.4–183.1)	22.9 (3.9–41.9)	0.02	0.22
N6 CT	160.2 (143.4–177.1)	187.3 (179.9–194.6)	27.0 (6.7–47.3)	0.01	0.21

^a Model 1 is adjusted for age and sex. Mean value: adjusted mean value.

^b Model 2 is adjusted for age, sex, and axial length. Mean value: adjusted mean value. CT, choroidal thickness.

reduced signal noise, and enhanced sweep depth, have significantly improved the visualization of choroidal layers. We improved the accuracy of choroidal segmentation and thickness measurements using a previously described novel sequential deep learning approach, which facilitated more precise segmentation of the choroid.³⁶ We observed that eyes treated with atropine in childhood exhibited thicker choroids in certain sectors compared to those that did not receive atropine. Similar differences were also noted in subgroup analyses, particularly in eyes treated with 0.01 % atropine or those treated for four years, compared to eyes that did not receive treatment. The affected choroid sectors included the outer superior, inner inferior, outer inferior, inner nasal, and outer nasal regions. In conclusion, our findings indicate that 2–4 years of topical atropine exposure during childhood was associated with choroidal thickness increases of 20–40 μm in certain sectors 10–20 years after treatment, compared to placebo, after adjusting for age, sex, and axial length. Furthermore, thicker choroidal measurements correlated with a reduced incidence of tessellated fundus in early adulthood. While our previous study demonstrated that childhood atropine treatment did not affect final refractive errors, this study provides new insights into the long-term effects of atropine on choroidal thickness. These findings contribute to the understanding of how atropine exposure during childhood may influence ocular development beyond refractive outcomes, supporting the potential long-term benefits of atropine in the treatment of childhood myopia.

This choroidal analysis from our ATLAS cohort examined the potential association between childhood exposure to atropine and choroidal thickness in adulthood, which may have implications for the long-term effects of atropine on myopia-related complications. Changes in choroidal thickness have been documented in children undergoing various myopia control interventions, such as orthokeratology,^{27,28,42,43}

topical atropine eye drops,^{29,31,32,44,45} and combination therapy.^{30,46} These changes have been suggested as predictors for myopia progression or axial elongation.²⁸ While studies have reported conflicting findings regarding choroidal thickness changes in response to myopic defocus in humans,⁴⁷ the effects of these interventions on the choroid are likely due to optical defocus. Short-term exposure to myopic defocus typically induces choroidal thickening, whereas hyperopic defocus results in choroidal thinning.^{48,49} However, these choroidal responses are often short-lived,⁵⁰ with thickness measurements generally returning to near baseline levels after cessation of treatment or removal of the defocus.^{51, 52} Interestingly, a recent study involving 46 participants demonstrated that choroidal thickness in children and adults does not significantly change in response to short-term, full-field myopic defocus, in contrast to several previously published studies.⁴⁷ Notably, another study found that 1 % atropine increased choroidal thickness, while 0.01 % atropine led to a decrease after six months of treatment.³² Similar short-term effects on choroidal thickness have also been observed in young myopic adults who either wore orthokeratology lenses⁵¹ or received low-dose atropine.⁵⁰ However, as most of these studies focused on short-term effects, our study contributes to the understanding of how childhood exposure to atropine treatment may have long-term effects on choroidal thickness.

Our results suggest that exposure to atropine during childhood may affect choroidal thickness in early adulthood; however, the differences in choroidal thickness measurements among the atropine treatment groups, averaging 20–40 μm, were less significant after adjusting for axial length. Subgroup analyses focusing on various concentrations and durations of atropine treatment found significant differences between the 0.01 % atropine group and those treated for four years (Tables 2–3). The relatively smaller sample size of the 1 % atropine-treated eyes and a

Table 2
Associations of Choroidal Thickness in Adulthood with 0.01 % Atropine Treatment in Childhood.

CT at Different Sectors, μm	Mean (95 % CI)		Mean Difference (95 % CI)	P Value	Adjusted R ²
	No Atropine (n = 94)	0.01 % Atropine (n = 56)			
Model 1^a					
Central subfield CT	213.5 (189.3–237.8)	267.7 (232.1–303.3)	54.2 (–0.4–108.7)	0.05	0.03
Inner superior CT	225.5 (201.9–249.2)	271.4 (235.3–307.5)	45.9 (–8.6–100.3)	0.10	0.02
Outer superior CT	237.1 (213.0–261.3)	305.0 (268.6–341.4)	67.9 (12.6–123.1)	0.02	0.03
Inner inferior CT	200.5 (176.0–224.9)	283.6 (247.7–319.5)	83.1 (28.0–138.3)	0.003	0.06
Outer inferior CT	207.0 (184.6–229.5)	276.0 (241.7–310.4)	69.0 (17.2–120.8)	0.009	0.05
Inner temporal CT	223.0 (198.8–247.2)	281.0 (245.5–316.5)	58.0 (3.5–112.5)	0.04	0.03
Outer temporal CT	235.2 (212.5–258.0)	288.7 (255.3–322.1)	53.5 (2.2–104.7)	0.04	0.03
Inner nasal CT	193.2 (170.3–216.1)	258.0 (223.4–292.6)	64.8 (12.3–117.3)	0.02	0.04
Outer nasal CT	164.9 (144.2–185.7)	228.0 (196.7–259.4)	63.1 (15.5–110.6)	0.01	0.05
N1 CT	201.1 (177.7–224.5)	259.2 (224.0–294.5)	58.1 (4.6–111.6)	0.03	0.03
N2 CT	189.0 (165.9–212.1)	254.6 (219.8–289.4)	65.6 (12.8–118.4)	0.02	0.05
N3 CT	189.3 (165.9–212.7)	260.2 (224.9–295.4)	70.9 (17.4–124.3)	0.01	0.05
N4 CT	183.2 (160.4–205.9)	238.0 (203.7–272.4)	54.9 (2.7–107.0)	0.04	0.02
N5 CT	154.0 (133.7–174.3)	216.5 (185.9–247.1)	62.5 (16.1–109.0)	0.009	0.05
N6 CT	157.6 (136.7–178.5)	229.4 (197.9–261.0)	71.8 (23.9–119.7)	0.004	0.07
Model 2^b					
Central subfield CT	220.2 (197.6–242.8)	256.6 (223.6–289.6)	36.4 (–14.5–87.4)	0.16	0.21
Inner superior CT	230.1 (207.8–252.4)	262.6 (228.7–296.6)	32.6 (–19.0–84.1)	0.21	0.17
Outer superior CT	241.4 (218.0–264.8)	297.4 (262.3–332.4)	55.9 (2.4–109.5)	0.04	0.15
Inner inferior CT	206.8 (183.4–230.1)	273.5 (239.3–307.6)	66.7 (13.9–119.5)	0.01	0.20
Outer inferior CT	213.6 (191.6–235.6)	265.7 (232.2–299.2)	52.0 (1.2–102.9)	0.04	0.15
Inner temporal CT	228.6 (205.9–251.2)	271.3 (238.1–304.4)	42.7 (–8.5–93.9)	0.10	0.20
Outer temporal CT	239.1 (217.3–260.9)	281.5 (249.7–313.4)	42.5 (–6.8–91.7)	0.09	0.16
Inner nasal CT	199.8 (178.5–221.2)	246.8 (214.8–278.9)	47.0 (–1.9–95.9)	0.06	0.23
Outer nasal CT	170.8 (151.0–190.6)	218.8 (189.1–248.5)	48.0 (2.6–93.4)	0.04	0.19
N1 CT	207.8 (185.9–229.7)	247.8 (214.9–280.6)	40.0 (–10.2–90.1)	0.12	0.21
N2 CT	195.5 (174.0–217.0)	243.7 (211.5–276.0)	48.3 (–1.0–97.6)	0.06	0.23
N3 CT	196.1 (174.3–218.0)	248.9 (216.2–281.7)	52.8 (2.7–102.9)	0.04	0.22
N4 CT	188.6 (166.8–210.3)	228.9 (196.2–261.5)	40.3 (–9.6–90.1)	0.11	0.17
N5 CT	160.4 (141.3–179.6)	206.4 (177.7–235.2)	46.0 (2.1–89.9)	0.04	0.21
N6 CT	163.2 (142.9–183.5)	220.9 (190.5–251.4)	57.8 (11.2–104.3)	0.02	0.18

^a Model 1 is adjusted for age and sex. Mean value: adjusted mean value.

^b Model 2 is adjusted for age, sex, and axial length. Mean value: adjusted mean value. CT, choroidal thickness.

possible rebound effect in the higher concentration groups (0.1 % and 0.5 %) may have mitigated any potential impact on choroidal thickness. Future research is needed to explore whether longer durations of atropine treatment during childhood or early adolescence exert a more substantial influence on the choroid.

The underlying mechanisms of the effects of atropine on choroidal thickness remain unclear. Previous animal studies suggested that nitric oxide may play a role in the choroidal thickening observed with atropine use,^{53–55} potentially by affecting blood flow and the stromal components of the choroid through the relaxation of both vascular and nonvascular smooth muscles in the choroid. Additionally, dopamine may also contribute to this thickening effect. For instance, intravitreal injections of atropine in chicks have been shown to increase dopamine release from the retina,⁵⁶ and the use of D2 agonists has led to increased choroidal thickness in chicks fitted with negative lenses.⁵⁷ Interestingly, research has noted choroidal thinning during the process of accommodation,⁵⁸ likely due to biomechanical forces exerted between the ciliary muscle and the choroid.⁵⁹ Further studies are necessary to clarify these mechanisms underlying choroidal thickening.

We also demonstrated an independent association between thicker choroid and a reduced incidence of tessellated fundus in early adulthood. The presence of a tessellated fundus in early adulthood may serve as a crucial indicator for predicting the progression of pathological changes of the choroid.⁶⁰ Choroidal thinning has been associated with various ophthalmic conditions,⁶¹ including myopic macular degeneration (MMD), macular holes, and age-related macular degeneration (AMD).¹ Studies suggest that the degree of fundus tessellation correlates with choroidal thickness rather than axial length.⁶⁰ Particularly, thinner choroidal thickness in the inner and outer nasal sectors is associated with the presence of MMD, proving it to be a more precise biometric

parameter than age or axial length.⁶² Our findings, which highlighted that differences in choroidal thickness among treatment groups were predominantly observed in the inner and outer nasal sectors, align with previous observations that these sectors are associated with MMD development. This may be attributed to the typical progression of myopic chorioretinal atrophy, which generally begins around the optic disc before extending toward the macular region and eventually affecting the entire area.^{62,63}

This study has several limitations. First, our findings are based on follow-up data from participants in previous clinical trials, suggesting an association rather than a causative relationship. This indicates the need for further longitudinal studies to confirm our results. Nevertheless, our study is the first to investigate the association between atropine and choroidal thickness in adults, addressing an important gap in the literature. Second, the follow-up rate was only about one-quarter of the original participants from the trials, which may have introduced selection bias. However, the baseline characteristics of those recalled participants were generally representative of the original cohort.¹⁵ Third, the adjusted R² values in our models were relatively low, suggesting that other residual confounding factors might have influenced the observed associations. Nevertheless, our model 1 and model 2 adjusted for key confounders, including age, sex, and axial length. Fourth, we observed that differences in choroidal thickness were only confined to specific sectors, including the inner inferior, outer inferior, inner nasal, and outer nasal regions. These findings were consistent with previous studies on choroidal thickness and MMD development. Fifth, choroidal thickness could be affected by other factors, such as circadian rhythms, caffeine intake, and exercise, which could be the confounding factors in our results.

In conclusion, this study demonstrated that 2–4 years of atropine

Table 3
Associations of Choroidal Thickness with 4 Years of Atropine Treatment in Childhood.

CT at Different Sectors, μm	Mean (95 % CI)		Mean Difference (95 % CI)	P Value	Adjusted R ²
	No Atropine (n = 94)	4 Years of Treatment (n = 174)			
Model 1^a					
Central subfield CT	195.7 (166.1–225.2)	237.0 (220.0–254.0)	41.3 (–1.6–84.3)	0.06	0.06
Inner superior CT	209.7 (180.6–238.7)	243.0 (225.8–260.2)	33.3 (–9.4–76.1)	0.13	0.05
Outer superior CT	215.9 (186.4–245.4)	270.8 (253.3–288.3)	55.0 (11.6–98.4)	0.01	0.07
Inner inferior CT	184.9 (154.8–215.0)	238.5 (221.1–255.8)	53.5 (9.7–97.4)	0.02	0.07
Outer inferior CT	193.1 (165.5–220.6)	239.0 (222.6–255.4)	45.9 (5.3–86.5)	0.03	0.08
Inner temporal CT	208.9 (179.9–237.9)	248.9 (232.2–265.6)	40.0 (–2.2–82.2)	0.06	0.07
Outer temporal CT	221.1 (194.4–247.8)	261.1 (245.7–276.5)	40.0 (1.1–78.9)	0.04	0.08
Inner nasal CT	174.7 (146.1–203.4)	221.9 (204.9–238.9)	47.2 (5.1–89.3)	0.03	0.07
Outer nasal CT	147.5 (121.6–173.5)	194.0 (178.4–209.6)	46.5 (8.1–84.8)	0.02	0.07
N1 CT	182.8 (153.8–211.7)	224.7 (207.5–241.8)	41.9 (–0.7–84.4)	0.05	0.06
N2 CT	169.8 (140.8–198.8)	219.7 (202.5–236.9)	49.9 (7.3–92.5)	0.02	0.07
N3 CT	171.5 (142.3–200.7)	221.3 (204.0–238.6)	49.8 (6.8–92.8)	0.02	0.07
N4 CT	161.2 (133.0–189.3)	208.7 (192.0–225.4)	47.5 (6.1–88.9)	0.02	0.06
N5 CT	138.2 (112.3–164.0)	182.5 (167.2–197.8)	44.4 (6.4–82.3)	0.02	0.06
N6 CT	142.9 (115.6–170.0)	194.9 (178.8–211.1)	52.1 (12.0–92.1)	0.01	0.06
Model 2^b					
Central subfield CT	205.6 (179.0–232.2)	231.5 (216.3–246.7)	25.9 (–12.7–64.5)	0.19	0.26
Inner superior CT	217.6 (190.7–244.5)	238.3 (222.5–254.1)	20.7 (–18.7–60.2)	0.30	0.21
Outer superior CT	222.9 (194.5–251.2)	266.7 (250.1–283.4)	43.9 (2.3–85.5)	0.04	0.17
Inner inferior CT	196.9 (170.0–223.9)	232.1 (216.7–247.5)	35.2 (–4.0–74.3)	0.08	0.29
Outer inferior CT	204.2 (179.1–229.2)	233.1 (218.4–247.9)	29.0 (–7.8–65.7)	0.12	0.27
Inner temporal CT	217.8 (191.5–244.2)	243.9 (228.9–259.0)	26.1 (–12.1–64.3)	0.18	0.25
Outer temporal CT	227.3 (202.3–252.4)	257.5 (243.2–271.8)	30.2 (–6.2–66.5)	0.10	0.22
Inner nasal CT	185.5 (159.7–211.3)	215.9 (200.8–231.0)	30.4 (–7.4–68.2)	0.11	0.27
Outer nasal CT	157.1 (133.2–181.1)	188.8 (174.5–203.0)	31.6 (–3.7–67.0)	0.08	0.24
N1 CT	192.6 (166.2–219.1)	219.1 (203.6–234.6)	26.5 (–12.3–65.3)	0.18	0.24
N2 CT	180.7 (154.5–206.9)	213.6 (198.3–229.0)	33.0 (–5.4–71.4)	0.09	0.26
N3 CT	183.1 (157.0–209.3)	214.9 (200.0–230.3)	31.8 (–6.6–70.2)	0.10	0.28
N4 CT	170.3 (144.1–196.6)	203.6 (188.2–218.9)	33.2 (–5.3–71.7)	0.09	0.21
N5 CT	148.3 (124.4–172.2)	177.2 (163.2–191.2)	28.9 (–6.1–63.9)	0.11	0.23
N6 CT	152.3 (127.4–177.2)	189.9 (175.1–204.6)	37.6 (1.0–74.2)	0.04	0.22

^a Model 1 is adjusted for age and sex. Mean value: adjusted mean value.

^b Model 2 is adjusted for age, sex, and axial length. Mean value: adjusted mean value. CT, choroidal thickness.

exposure during childhood was associated with a relatively thicker choroid—by 20–40 μm in certain sectors—10–20 years after treatment compared to placebo, after adjusting for age, sex, and axial length. Furthermore, the increased choroidal thickness correlated with a reduced incidence of tessellated fundus in early adulthood. While it remains unclear whether this association indicates a causal relationship or is influenced by confounding factors, the findings further support the potential long-term benefits of topically applied atropine eye drops for the treatment of childhood myopia.

Financial support

This study was supported by the Singapore Health Services Duke-NUS Ophthalmology and Visual Sciences Academic Clinical Programme Research Fund (05/FY2019/EX/24-A74); National Medical Research Council, Singapore: MOH-000655–00 & MOH-001015–00; Duke-NUS Medical School: Duke-NUS/RSF/2021/0018 & 05/FY2020/EX/15-A58; Agency for Science, Technology and Research: A20H4g2141 & H20C6a0032.

Declaration of Competing Interest

Dr Jost B. Jonas has disclosed European patent EP 3 271 392, JP 2021–119187, and US 2021 0340237 A1: Agents for use in the therapeutic or prophylactic treatment of myopia or hyperopia. Dr Audrey Chia has disclosed royalties from Myopine. Dr Leopold Schmetterer has disclosed consultancy fee from Thea Pharma.

Appendix A. Supporting information

Supplementary data associated with this article can be found in the online version at doi:10.1016/j.apjo.2024.100107.

References

- Li Y, Foo LL, Wong CW, et al. Pathologic myopia: advances in imaging and the potential role of artificial intelligence. *Br J Ophthalmol.* 2023;107:600–606.
- Li Y, Yip MYT, Ting DSW, et al. Artificial intelligence and digital solutions for myopia. *Taiwan J Ophthalmol.* 2023;13:142–150.
- Li Y, Zheng F, Foo LL, et al. Advances in OCT imaging in myopia and pathologic myopia. *Diagnostics.* 2022;12:1418.
- Baird PN, Saw SM, Lanca C, et al. Myopia. *Nat Rev Dis Prim.* 2020;6:99.
- Holden BA, Fricke TR, Wilson DA, et al. Global prevalence of myopia and high myopia and temporal trends from 2000 through 2050. *Ophthalmology.* 2016;123:1036–1042.
- Bullimore MA, Ritchey ER, Shah S, et al. The risks and benefits of myopia control. *Ophthalmology.* 2021;128:1561–1579.
- Modjtahedi BS, Abbott RL, Fong DS, et al. Reducing the global burden of myopia by delaying the onset of myopia and reducing myopic progression in children: the academy’s task force on Myopia. *Ophthalmology.* 2021;128:816–826.
- Chua WH, Balakrishnan V, Chan YH, et al. Atropine for the treatment of childhood myopia. *Ophthalmology.* 2006;113:2285–2291.
- Chia A, Chua WH, Cheung YB, et al. Atropine for the treatment of childhood myopia: safety and efficacy of 0.5%, 0.1%, and 0.01% doses (Atropine for the Treatment of Myopia 2). *Ophthalmology.* 2012;119:347–354.
- Zadnik K, Schulman E, Flitcroft I, et al. Efficacy and Safety of 0.01% and 0.02% atropine for the treatment of pediatric myopia progression over 3 years: a randomized clinical trial. *JAMA Ophthalmol.* 2023;141:990–999.
- Gong Q, Janowski M, Luo M, et al. Efficacy and adverse effects of atropine in childhood myopia: a meta-analysis. *JAMA Ophthalmol.* 2017;135:624–630.
- Sacchi M, Serafino M, Villani E, et al. Efficacy of atropine 0.01% for the treatment of childhood myopia in European patients. *Acta Ophthalmol.* 2019;97:e1136–e1140.
- Chia A, Lu QS, Tan D. Five-year clinical trial on atropine for the treatment of myopia 2: myopia control with atropine 0.01% eyedrops. *Ophthalmology.* 2016;123:391–399.

14. Yam JC, Zhang XJ, Zhang Y, et al. Effect of low-concentration atropine eyedrops vs placebo on myopia incidence in children: the LAMP2 randomized clinical trial. *JAMA*. 2023;329:472–481.
15. Li Y, Yip M, Ning Y, et al. Topical atropine for childhood myopia control: the atropine treatment long-term assessment study. *JAMA Ophthalmol*. 2024;142:15–23.
16. Summers JA. The choroid as a sclera growth regulator. *Exp Eye Res*. 2013;114:120–127.
17. Flores-Moreno I, Lugo F, Duker JS, et al. The relationship between axial length and choroidal thickness in eyes with high myopia. *Am J Ophthalmol*. 2013;155:314–319.
18. Wang NK, Lai CC, Chu HY, et al. Classification of early dry-type myopic maculopathy with macular choroidal thickness. *Am J Ophthalmol*. 2012;153:669–677.
19. Ahn SJ, Park KH, Woo SJ. Subfoveal choroidal thickness changes following anti-vascular endothelial growth factor therapy in myopic choroidal neovascularization. *Invest Ophthalmol Vis Sci*. 2015;56:5794–5800.
20. Li Z, Wang W, Liu R, et al. Choroidal thickness predicts progression of myopic maculopathy in high myopes: a 2-year longitudinal study. *Br J Ophthalmol*. 2021;105:1744–1750.
21. Copete S, Flores-Moreno I, Montero JA, et al. Direct comparison of spectral-domain and swept-source OCT in the measurement of choroidal thickness in normal eyes. *Br J Ophthalmol*. 2014;98:334–338.
22. Hirata M, Tsujikawa A, Matsumoto A, et al. Macular choroidal thickness and volume in normal subjects measured by swept-source optical coherence tomography. *Invest Ophthalmol Vis Sci*. 2011;52:4971–4978.
23. Ronneberger O, Fischer P., Brox T. U-net: Convolutional Networks for Biomedical Image Segmentation. Medical Image Computing and Computer-Assisted Intervention – MICCAI 2015: 18th International Conference. Munich, Germany. 2015.
24. Gu Z, Cheng J, Fu H, et al. Ce-net: context encoder network for 2d medical image segmentation. *IEEE Trans Med Imaging*. 2019;38:2281–2292.
25. Kugelman J, Alonso-Caneiro D, Read SA, et al. Automatic choroidal segmentation in OCT images using supervised deep learning methods. *Sci Rep*. 2019;9, 13298.
26. Masood S, Fang R, Li P, et al. Automatic choroid layer segmentation from optical coherence tomography images using deep learning. *Sci Rep*. 2019;9:3058.
27. Li Z, Cui D, Hu Y, et al. Choroidal thickness and axial length changes in myopic children treated with orthokeratology. *Cont Lens Anterior Eye*. 2017;40:417–423.
28. Li Z, Hu Y, Cui D, et al. Change in subfoveal choroidal thickness secondary to orthokeratology and its cessation: a predictor for the change in axial length. *Acta Ophthalmol*. 2019;97:e454–e459.
29. Zhang Z, Zhou Y, Xie Z, et al. The effect of topical atropine on the choroidal thickness of healthy children. *Sci Rep*. 2016;6, 34936.
30. Zhao W, Li Z, Hu Y, et al. Short-term effects of atropine combined with orthokeratology (ACO) on choroidal thickness. *Cont Lens Anterior Eye*. 2021;44, 101348.
31. Li W, Jiang R, Zhu Y, et al. Effect of 0.01% atropine eye drops on choroidal thickness in myopic children. *J Fr Ophthalmol*. 2020;43:862–868.
32. Ye L, Shi Y, Yin Y, et al. Effects of atropine treatment on choroidal thickness in myopic children. *Invest Ophthalmol Vis Sci*. 2020;61:15.
33. Tong L, Huang XL, Koh ALT, et al. Atropine for the treatment of childhood myopia: effect on myopia progression after cessation of atropine. *Ophthalmology*. 2009;116:572–579.
34. Mrejen S, Spaide RF. Optical coherence tomography: imaging of the choroid and beyond. *Surv Ophthalmol*. 2013;58:387–429.
35. Jin P, Zou H, Zhu J, et al. Choroidal and retinal thickness in children with different refractive status measured by swept-source optical coherence tomography. *Am J Ophthalmol*. 2016;168:164–176.
36. Cahyo D.A.Y., Wong D.W.K., Yow A.P., et al. Volumetric Choroidal Segmentation Using Sequential Deep Learning Approach in High Myopia Subjects. *Annu Int Conf IEEE Eng Med Biol Soc*. 2020;1286–1289.
37. Cahyo D, Yow AP, Saw SM, et al. Volumetric choroidal segmentation with a novel deep learning approach fusing spatial information. *Invest Ophthalmol Vis Sci*. 2021;62:2156.
38. Novikov AA, Major D, Wimmer M, et al. Deep sequential segmentation of organs in volumetric medical scans. *IEEE Trans Med Imaging*. 2019;38:1207–1215.
39. Williams RL. A note on robust variance estimation for cluster-correlated data. *Biometrics*. 2000;56:645–646.
40. He X, Jin P, Zou H, et al. Choroidal thickness in healthy Chinese children aged 6 to 12: the Shanghai children eye study. *Retina*. 2017;37:368–375.
41. Karapetyan A, Ouyang P, Tang LS, et al. Choroidal thickness in relation to ethnicity measured using enhanced depth imaging optical coherence tomography. *Retina*. 2016;36:82–90.
42. Chen Z, Xue F, Zhou J, et al. Effects of orthokeratology on choroidal thickness and axial length. *Optom Vis Sci*. 2016;93:1064–1071.
43. Xiao J, Pan X, Hou C, et al. Changes in subfoveal choroidal thickness after orthokeratology in myopic children: a systematic review and meta-analysis. *Curr Eye Res*. 2024;49:683–690.
44. Chiang STH, Turnbull PRK, Phillips JR. Additive effect of atropine eye drops and short-term retinal defocus on choroidal thickness in children with myopia. *Sci Rep*. 2020;10, 18310.
45. Wu J, Gong H, Li H, et al. Changes in choroidal thickness in myopic children with 0.01% atropine: Evidence from a 12-month follow-up. *Photo Photo Ther*. 2023;42, 103528.
46. Hao Q, Zhao Q. Changes in subfoveal choroidal thickness in myopic children with 0.01% atropine, orthokeratology, or their combination. *Int Ophthalmol*. 2021;41:2963–2971.
47. Ostrin LA, Sah RP, Queener HM, et al. Short-term myopic defocus and choroidal thickness in children and adults. *Invest Ophthalmol Vis Sci*. 2024;65:22.
48. Wang D, Chun RKM, Liu M, et al. Optical defocus rapidly changes choroidal thickness in schoolchildren. *PLoS One*. 2016;11, e0161535.
49. Hoseini-Yazdi H, Vincent SJ, Collins MJ, et al. Regional alterations in human choroidal thickness in response to short-term monocular hemifield myopic defocus. *Ophthalmic Physiol Opt*. 2019;39:172–182.
50. Sander BP, Collins MJ, Read SA. Short-term effect of low-dose atropine and hyperopic defocus on choroidal thickness and axial length in young myopic adults. *J Ophthalmol*. 2019, 4782536.
51. Lee JH, Hong IH, Lee TY, et al. Choroidal thickness changes after orthokeratology lens wearing in young adults with myopia. *Ophthalmic Res*. 2021;64:121–127.
52. Chakraborty R, Read SA, Collins MJ. Monocular myopic defocus and daily changes in axial length and choroidal thickness of human eyes. *Exp Eye Res*. 2012;103:47–54.
53. Nickla DL, Wilken E, Lytle G, et al. Inhibiting the transient choroidal thickening response using the nitric oxide synthase inhibitor L-NAME prevents the ameliorative effects of visual experience on ocular growth in two different visual paradigms. *Exp Eye Res*. 2006;83:456–464.
54. Nickla DL, Wildsoet CF. The effect of the nonspecific nitric oxide synthase inhibitor NG-nitro-L-arginine methyl ester on the choroidal compensatory response to myopic defocus in chickens. *Optom Vis Sci*. 2004;81:111–118 81:111–118.
55. Carr BJ, Stell WK. Nitric oxide (NO) mediates the inhibition of form-deprivation myopia by atropine in chicks. *Sci Rep*. 2016;6:9.
56. Schwahn HN, Kaymak H, Schaeffel F. Effects of atropine on refractive development, dopamine release, and slow retinal potentials in the chick. *Vis Neurosci*. 2000;17:165–176.
57. Nickla DL, Totonelly K, Dhillon B. Dopaminergic agonists that result in ocular growth inhibition also elicit transient increases in choroidal thickness in chicks. *Exp Eye Res*. 2010;91:715–720.
58. Woodman-Pieterse EC, Read SA, Collins MJ, et al. Regional changes in choroidal thickness associated with accommodation. *Invest Ophthalmol Vis Sci*. 2015;56:6414–6422.
59. Croft MA, Nork TM, McDonald JP, et al. Accommodative movements of the vitreous membrane, choroid, and sclera in young and presbyopic human and nonhuman primate eyes. *Invest Ophthalmol Vis Sci*. 2013;54:5049–5058.
60. Yoshihara N, Yamashita T, Ohno-Matsui K, et al. Objective analyses of tessellated fundi and significant correlation between degree of tessellation and choroidal thickness in healthy eyes. *PLoS One*. 2014;9, e103586.
61. Read SA, Fuss JA, Vincent SJ, et al. Choroidal changes in human myopia: insights from optical coherence tomography imaging. *Clin Exp Optom*. 2019;102:270–285.
62. Liu R, Xuan M, Wang DC, et al. Using choroidal thickness to detect myopic macular degeneration. *Int J Ophthalmol*. 2024;17:317–323.
63. Liu Y, Wang L, Xu Y, et al. The influence of the choroid on the onset and development of myopia: from perspectives of choroidal thickness and blood flow. *Acta Ophthalmol*. 2021;99:730–738.